

## Changes in root length during orthodontic treatment: advantages for immature teeth

Maria Mavragani, Olav Egil Bøe, Per Johan Wisth and Knut Andreas Selvig

Departments of Orthodontics and Facial Orthopedics, and Dental Research, Faculty of Dentistry, University of Bergen, Norway

**SUMMARY** The purpose of the study was to investigate root lengthening during orthodontic treatment in relation to the age of the patient, the developmental stage of the root, and the anticipated growth. Specifically, the potential benefit of treating young teeth was addressed.

The sample consisted of 80 patients with Angle Class II division 1 malocclusions, treated with extraction of at least two maxillary first premolars, and edgewise technique with 0.018-inch slot brackets. Additionally, a cross-sectional control group of 66 untreated individuals matched to gender, and pre- and post-treatment age of the experimental group was included. Crown and root lengths of the maxillary incisors were measured on peri-apical radiographs before and after treatment, and corrected for image distortion. The stage of root development before treatment was recorded.

Root elongation during treatment was found for 50 out of the 280 examined teeth. Age at treatment start was significantly higher among the patients showing root shortening of the lateral incisors during treatment than among those showing root elongation ( $P < 0.05$ ). The stage of root development was significantly related to the direction of root length change, i.e. shortening or elongation. Roots elongated during treatment did not differ in length from untreated teeth of similarly aged individuals. There was no significant difference in the extent of root lengthening between the roots elongated during treatment and the normal root lengthening in age-matched untreated individuals. Post-treatment root length was significantly related to pre-treatment age. Roots that were incompletely developed before treatment reached a significantly greater length than those that were fully developed at the start of treatment.

The results of this study show a definite advantage for younger teeth with regard to post-treatment root length. This finding may influence treatment planning strategy.

### Introduction

Root shortening as a result of apical root resorption is a possible side-effect of orthodontic treatment. Mean values ranging from 0.5 to 3.0 mm of root shortening during treatment have been reported (Brezniak and Wasserstein, 1993).

In radiographic comparison of two orthodontic techniques with regard to the severity of apical root resorption, it was found that some teeth increased in root length during the treatment period (Mavragani *et al.*, 2000). Such findings may either be attributed to a real increase of root length (Linge and Linge, 1983) or to method error (Mirabella and Årtun, 1995; Baumrind

*et al.*, 1996). Due to age range and biological variation, some teeth will have a growth potential at the start of treatment. Thus, root growth even if followed by resorption might result in root elongation.

The application of gentle forces on immature teeth has been reported to have little effect on their predestined root length (Rudolph, 1936). The younger the patient at the onset of treatment, the more prolonged the treatment could be without permanent loss of root tip structure (Rudolph, 1940). A study of root resorption of canines and premolars during Begg orthodontic treatment concluded that incompletely formed roots reached their predestined length (Rosenberg, 1972).

The aim of this study was to investigate more closely the relationship between root lengthening of maxillary incisors during orthodontic treatment, the age of the patient, and the developmental stage of the root, and to compare it with growth in age and gender-matched untreated individuals. The root length of treated teeth showing root lengthening was compared with the root length of similar untreated teeth and the length of the roots showing resorption. In that way, any potential benefit from early orthodontic treatment for tooth root length could be evaluated.

### Subjects and methods

The material comprised the records of 80 patients treated with straight-wire and standard edgewise technique with 0.018-inch slot brackets in the Postgraduate Clinic, Department of Orthodontics and Facial Orthopedics, University of Bergen. Sixty-six individuals who did not require orthodontic treatment served as the control group. All four maxillary incisors were studied.

All patients had an Angle Class II division 1 malocclusion. They were treated with extraction of two maxillary first premolars, four first premolars, or two maxillary first and mandibular second premolars. The group consisted of 42 males and 38 females with a mean age of 12.7 years (range 8.0–35.5; SE 0.5) at the start of active treatment. Crown and root lengths of the maxillary incisors were measured on pre- and post-treatment peri-apical radiographs and corrected for image distortion. Root development was characterized as complete or incomplete, depending on whether or not the root apex was closed (stage XV; Gleiser and Hunt, 1955; Fanning, 1961). Root length loss in millimetres was calculated. The experimental group was used in an earlier study, where the criteria for exclusion of teeth due to unacceptable quality of radiographs and the method of assessment of root length change are described in detail (Mavragani *et al.*, 2000).

Forty patients were treated with standard and 40 with the straight-wire edgewise technique. Since significant differences were found in the amount of apical root resorption after treatment with the two techniques (Mavragani *et al.*, 2000), it was

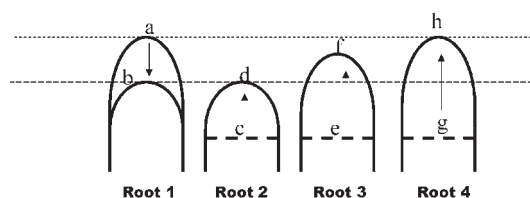
necessary to ascertain that the distribution of the two treatment techniques was balanced with regard to patients with incomplete and fully developed roots, as well as with regard to age at the onset of treatment. For that purpose a Chi-square test was used to compare patients with mature and immature roots with regard to treatment technique for each tooth separately. A two-sample *t*-test was also performed to determine whether there was a significant difference in the pre-treatment age between the two treatment subgroups.

The mean root length change during treatment for each of the maxillary incisors was calculated. Negative values indicated root elongation. Since age was a significant explanatory variable for the amount of root resorption (Mavragani *et al.*, 2000), its effect on the direction of root length alteration (elongation or shortening) was evaluated. A Mann–Whitney test was used to test for any difference in the age of the patients showing root shortening and those showing root elongation for each tooth. In the statistical handling of the data, non-parametric tests were used when the sample sizes were small, as in the number of teeth with elongated roots.

In order to evaluate whether roots that were elongated during treatment differed from those that were shortened regarding pre-treatment stage of root development, a Chi-square test was performed for teeth 12 and 22, and the non-parametric Fisher's exact test for teeth 11 and 21.

The hypothesis tested was that roots which elongate during treatment may reach a length equal to or exceeding the post-treatment length of fully developed roots, which are likely to undergo shortening by resorption (Figure 1). In the first case, the summation of the potential growth and the expected shortening due to resorption would result in a root length equal to that of mature shortened roots. In the second case, there would be a real advantage for the immature elongated roots. To examine these two possibilities, the post-treatment length of the roots showing reduction was compared with the elongated roots by a Mann–Whitney test for each tooth.

Teeth showing an increase in root length during treatment were compared with non-treated



**Figure 1** Diagrammatic representation of changes in apical topography during orthodontic treatment. Root 1 was resorbed apically from level a, which represents the normal incisor length, to level b. Root 2 was elongated during treatment from c to d, reaching the same post-treatment length as root 1. Root 3 was elongated during treatment from e to f, and exceeded the length of root 1. Root 4 developed from g reaching length h equal to the normal length a. Only roots 3 and 4, but not root 2, show real benefit with regard to final root length, although all of them show 'elongation' during treatment.

teeth. For that purpose a control group was chosen according to a cross-sectional design. This group consisted of two subgroups of 33 untreated individuals each, matched for gender to the group of orthodontic patients showing root elongation. In addition, the first control subgroup matched the pre-treatment age of the patients with root length increase, while the second subgroup matched the post-treatment age of these patients. Chi-square and two-sample *t*-tests were performed to ascertain similarity of the experimental and control groups.

In order to investigate whether the lengthened roots had reached the root length of untreated teeth, the post-treatment root length was compared with the root length of the control subgroup with matching post-treatment age, using a Mann–Whitney test for each of the study teeth. The difference in root lengthening between the control group and the patients with

elongated roots during treatment was similarly tested.

The effect of pre-treatment age, developmental stage of the roots before treatment and treatment duration on the post-treatment root length was evaluated by regression analysis. Post-treatment root length was used as the dependent variable and the remaining variables as regressors. Additionally, the post-treatment length of incomplete roots was compared with the length of the roots completed before treatment, using a Mann–Whitney test.

The statistical analyses were carried out using the Minitab software package (Minitab Data Analysis Software, State College, PA, USA).

## Results

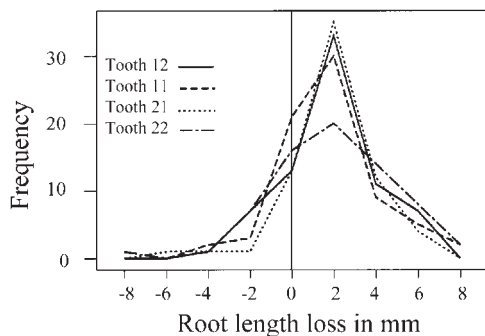
No significant relationship was found between pre-treatment age and the treatment technique used ( $P = 0.496$ ). Similarly, there was no significant difference between teeth with complete or incomplete roots in relation to treatment technique ( $P = 0.23$  for tooth 12,  $P = 0.17$  tooth 11,  $P = 0.56$  tooth 21, and  $P = 0.11$  tooth 22).

Evaluation of the root length change during treatment revealed a mean root length loss of 1.86 mm (SE 0.26; range –3.8 to 6.54 mm) for tooth 12, 1.82 mm (SE 0.26; range –3.82 to 8.9 mm) for tooth 11, 1.93 mm (SE 0.25; range –5.7 to 6.27 mm) for tooth 21, and 1.78 mm (SE 0.33; range –8.39 to 7.48) for tooth 22. Negative values indicating root elongation were recorded for 50 out of 280 teeth (Table 1; Figure 2).

Pre-treatment age was significantly higher among the patients showing root shortening of the lateral incisors than among those showing root elongation ( $P < 0.05$ ). For the central incisors the age difference was not significant (Table 1).

**Table 1** Pre-treatment age of patients showing root shortening and root elongation per study tooth.

Tooth no.	Root shortening			Root elongation			
	<i>n</i>	Median age (years)	Range	<i>n</i>	Median age (years)	Range	<i>P</i>
12	59	12.8	8.0–35.5	13	11.5	8.8–14.9	0.006
11	60	12.5	8.8–35.5	12	12.0	8.0–14.9	0.330
21	58	12.1	8.8–35.5	9	12.9	10.4–14.9	0.679
22	53	12.9	8.0–35.5	16	11.6	8.8–15.3	0.015



**Figure 2** Frequency distribution of root length loss during orthodontic treatment. Negative values, on the left of the vertical line, indicate root elongation.

There was a significant difference for three of the maxillary incisors when considering the pre-treatment stage of root development between shortened and elongated roots, with the elongated roots being more often undeveloped before treatment ( $P = 0.002$  for tooth 12,  $P = 0.030$  tooth 11,  $P = 0.356$  tooth 21, and  $P = 0.014$  tooth 22).

Elongated roots reached significantly greater length than those that were shortened during treatment. The difference was significant at the 0.1 per cent level for lateral incisors and at the 1 per cent level for tooth 11. However, the post-treatment length of the roots elongated during treatment did not differ significantly from those of untreated teeth in individuals of the same age (Table 2); thus, the length increase of the elongated roots did not differ from that of the control group during a period equal to the treatment duration. For tooth 12 the median value for root length change of elongated roots

was 1.21 mm and the length increase of control roots 0.92 mm ( $P = 0.65$ ). Similarly, for tooth 11 the median value for the lengthened roots was 0.68 mm and for the control roots 0.82 mm ( $P = 0.63$ ). The median of the amount of elongation for 21 was 0.85 mm and of control roots  $-0.08$  mm ( $P = 0.12$ ). For tooth 22 the median for the elongation was 1.16 mm, while that of the control roots 1.71 mm ( $P = 0.74$ ).

Regression analysis revealed that post-treatment root length of all study teeth was significantly related to age at the start of treatment. The stage of root development showed a significant correlation coefficient only for the lateral incisors (Table 3).

In three of the study teeth, roots that were immature at the start of treatment reached a significantly greater length than those that were already fully developed before treatment. The difference was significant for tooth 12 (median post-treatment length of roots completed before treatment 14.71 mm and of uncompleted roots 17.46 mm,  $P = 0.003$ ), tooth 21 (corresponding values: 15.30 mm, 18.98 mm,  $P = 0.025$ ), and tooth 22 (14.14 mm, 17.79 mm,  $P = 0.003$ ). For tooth 11 the difference did not reach statistical significance (15.51 mm, 16.98 mm,  $P = 0.111$ ).

## Discussion

In the patient sample studied, there was an even distribution of the two treatment techniques between the younger and older patients having immature or completed roots. Consequently, the difference in the amount of root resorption previously reported between the two techniques

**Table 2** Post-treatment root lengths. Comparison of elongated roots with shortened roots and corresponding roots in age and gender-matched untreated individuals.

Tooth no.	Elongated roots			Shortened roots			<i>P</i>	Control roots			<i>P</i>
	<i>n</i>	Median (mm)	Range	<i>n</i>	Median (mm)	Range		<i>n</i>	Median (mm)	Range	
12	13	17.36	13.21–19.28	59	14.55	9.27–19.03	0.000	33	17.03	12.00–21.43	0.81
11	12	17.56	14.32–22.03	60	15.32	9.13–20.67	0.003	30	16.79	14.29–22.92	0.46
21	9	15.52	14.10–22.25	58	15.30	9.13–20.59	0.251	29	16.69	14.27–23.64	0.30
22	16	16.85	13.82–20.45	53	13.77	8.55–19.78	0.000	31	17.48	12.99–22.14	0.86

**Table 3** Post-treatment root length as related to pre-treatment age, treatment duration, and stage of root development. Regression analysis with post-treatment root length as dependent variable.  $R^2$  (adj) corresponds to the explained variance. Regression coefficients corresponding to each of the explanatory variables.

Tooth no.	<i>n</i>	Constant	$R^2$ (adj) (%)	Pre-treatment age	Root development	Treatment duration
12	72	17.06	18.9	-0.013**	2.151**	-0.008
11	72	16.83	7.6	-0.012*	1.547	0.028
21	67	17.12	7.7	-0.011*	2.789	-0.003
22	69	17.68	21.3	-0.016**	2.349**	-0.026

\* $P \leq 0.05$ , \*\* $P \leq 0.01$ .

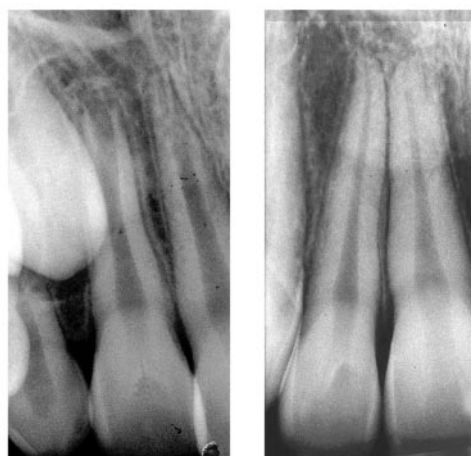would not bias further analysis (Mavragani *et al.*, 2000).

While the experimental group was followed longitudinally, the control group was cross-sectional as it was not considered ethically acceptable to follow-up radiographically individuals who did not require treatment. Two variables, age and root development, were evaluated. For clinical purposes chronological age, which is easily available, reveals some information about root development. The assessment of the stage of root development requires radiographic examination, but does not give definite information about the cellular activity at the root apex. That may be the reason why final root length of the central incisors was significantly related with pre-treatment age, but not with the developmental stage of the root before treatment (Table 3). Roots that appear complete radiographically may still increase in root length.

Stage XV of tooth formation was used to define roots as completely developed. This stage corresponds to 'complete apex closure' (Fanning, 1961) or to 'terminally convergent root canal' (Gleiser and Hunt, 1955), being the last developmental stage in both classifications. In this study, stage XIV in Fanning's (1961) classification that describes 'complete root length' could have been used. However, since the definite root length is not known in advance, it is difficult to determine whether a root has reached its final length while the apex is still open. Moreover, the same stage (XIV) corresponds to 'terminally divergent root canal' of Gleiser and Hunt's (1955) classification in which root length is not necessarily considered complete.

The relatively frequent finding of root elongation during treatment could have been caused by method error. However, the positive relationship of the direction of root length change (elongation or shortening) with pre-treatment age and developmental stage of the root indicates that residual growth is the major contributing factor (Figure 3).

The next part of the study aimed to determine the effect of root elongation during treatment on final root length, and whether this length was different from that of teeth which were fully developed but may have suffered apical resorption during treatment. The results show that the younger teeth reach a greater final length, which is equal to the root length of untreated teeth, meaning that treatment did not have any negative



**Figure 3** Pre- and post-treatment radiographs of a lateral incisor, which completed root development during the period of orthodontic treatment.

influence on the root length in teeth with incomplete roots. The final root length was related to the pre-treatment age and was significantly greater for roots that were incompletely developed at the start of treatment. This is an indication that a mechanism exists which protects the younger roots against apical resorption during treatment. This finding is in partial agreement with an investigation of apical root resorption of posterior teeth by Hendrix *et al.* (1994). Those authors also found lengthening of teeth with incomplete root formation that did not reach the normal root length. They suggested that teeth with incomplete root formation have a higher resistance against root resorption and recommended, as far as posterior root resorption is concerned, that orthodontic treatment is commenced before root formation is finished. From the present study, it seems likely that the same conclusion is also valid for anterior teeth.

Random measurement error may explain some of the negative values found for apical resorption, particularly in adult patients (Baumrind *et al.*, 1996). As stated by Mirabella and Årtun (1995), root development during treatment is highly unlikely in adults. However, cementum is deposited continuously throughout life (Zander and Hürzeler, 1958), and is approximately tripled in thickness between 11 and 76 years of age. The increase is most pronounced in the apical area. Van der Linden and Duterloo (1976) also described progressive deposition of cementum, particularly at the apex. They observed that the apices of all teeth become rounded due to continued cementum deposition, a sign of dentitional ageing. On the other hand, Bishara *et al.* (1999), who evaluated the physiological changes in root length from early to mid-adulthood, found neither resorption nor apposition on the roots of all teeth evaluated between 25 and 45 years of age. Moreover, compensatory cementum formation may occur in association with orthodontic tooth movement, forced eruption, or occlusal hyperfunction (Grant and Bernick, 1972; Ash and Ramfjord, 1995). In interpreting the negative values for root resorption, the possibility of root lengthening of teeth of adult patients because of cementum apposition, therefore, should not be disregarded.

In a histological investigation, Reitan (1974) noticed that apical root resorption does not prevent further development of roots in which there is a fairly thick pre-dentine layer. He suggested that since uncalcified pre-dentine is not attacked by resorbing cells, a permanent distraction of the apical part of the root may be avoided if tooth movement is carried out before the apical part is fully developed.

Nevertheless, root development can be affected by tooth movement. During orthodontic treatment of uncompleted roots, dilaceration may result from the deflection of the Hertwig's epithelial sheath. Stenvik and Mjör (1970) found frequent disturbances in root formation, including deviation from the normal direction of root development and morphological changes in the tissue formed during tooth movement. Teeth with open apices exhibited less severe pulp changes, such as circulatory disturbances and vacuolization, than those with complete root development, indicating greater biological tolerance in root-open teeth.

The behaviour of autotransplanted teeth seems to be similar. Orthodontic treatment has no adverse effect on their root development (Lagerström and Kristerson, 1986). No significant difference was found between final root length of autotransplanted premolars that were treated orthodontically and those that were not. With regard to root growth of autotransplanted teeth, Slagvold and Bjercke (1974) speculated that the epithelial sheath of a tooth has a strong capacity to survive and for its growth potential to be expressed. That seems to be effective even during orthodontic tooth movement. The root forming tissues that surround the undeveloped tooth complete their assignment by protecting at the same time the mineralized root tissues from apical resorption during orthodontic treatment.

## Conclusions

This study showed a definite advantage for younger teeth with regard to post-treatment root length. Since root shortening due to apical resorption is one of the most serious side-effects of orthodontic treatment, it appears advisable to initiate orthodontic correction of the incisors at a



young age during the mixed dentition, in an introductory phase of treatment. The occlusion must then be retained until the remaining permanent teeth have erupted and a second phase of treatment can follow. This strategy may require additional treatment time, but in addition to the early aesthetic benefit for the patient, the anterior teeth are protected against root shortening and dental tissue is preserved.

### Address for correspondence

Maria Mavragani  
Department of Dental Research  
Faculty of Dentistry  
University of Bergen  
Årstadveien 17  
N-5009 Bergen  
Norway

### Acknowledgements

We are greatly indebted to Mr H. C. Olsen, former engineer of the Laboratory of Dental Research, for proficient support and assistance. We wish to express our gratitude to Drs N. J. Selliseth and P. Brudvik, for generous help and advice.

### References

- Ash M M, Ramfjord S P 1995 Occlusion, 4th edn. W.B. Saunders Company, Philadelphia
- Baumrind S, Korn E L, Boyd R L 1996 Apical root resorption in orthodontically treated adults. *American Journal of Orthodontics and Dentofacial Orthopedics* 110: 311–320
- Bishara S E, VonWald L, Jakobsen J R 1999 Changes in root length from early to mid-adulthood: resorption or apposition? *American Journal of Orthodontics and Dentofacial Orthopedics* 115: 563–568
- Brezniak N, Wasserstein A 1993 Root resorption after orthodontic treatment: part 1. Literature review. *American Journal of Orthodontics and Dentofacial Orthopedics* 103: 62–66
- Fanning E 1961 A longitudinal study of tooth formation and root resorption. *New Zealand Dental Journal* 57: 202–217
- Gleiser I, Hunt E E 1955 The permanent mandibular first molar: its calcification, eruption and decay. *American Journal of Physical Anthropology* 13: 253–283
- Grant D, Bernick S 1972 The periodontium of ageing humans. *Journal of Periodontology* 43: 660–667
- Hendrix I, Carels C, Kuijpers-Jagtman A M, van 't Hof M 1994 A radiographic study of posterior apical root resorption in orthodontic patients. *American Journal of Orthodontics and Dentofacial Orthopedics* 105: 345–349
- Lagerström L, Kristerson L 1986 Influence of orthodontic treatment on root development of autotransplanted premolars. *American Journal of Orthodontics* 89: 146–150
- Linge B O, Linge L 1983 Apical root resorption in upper anterior teeth. *European Journal of Orthodontics* 5: 173–183
- Mavragani M, Vergari A, Selliseth N J, Bøe O E, Wisth P J 2000 A radiographic comparison of apical root resorption after orthodontic treatment with a standard edgewise and a straight-wire edgewise technique. *European Journal of Orthodontics* 22: 665–674
- Mirabella A D, Årtun J 1995 Prevalence and severity of apical root resorption of maxillary anterior teeth in adult orthodontic patients. *European Journal of Orthodontics* 17: 93–99
- Reitan K 1974 Initial tissue behavior during apical root resorption. *Angle Orthodontist* 44: 68–82
- Rosenberg M N 1972 An evaluation of the incidence and amount of apical root resorption and dilaceration occurring in orthodontically treated teeth having incompletely formed roots at the beginning of Begg treatment. *American Journal of Orthodontics* 61: 524–525
- Rudolph C E 1936 A comparative study in root resorption in permanent teeth. *Journal of the American Dental Association* 23: 822–826
- Rudolph C E 1940 An evaluation of root resorption occurring during orthodontic treatment. *Journal of Dental Research* 19: 367–371
- Slagsvold O, Bjercke B 1974 Autotransplantation of premolars with partly formed roots. *American Journal of Orthodontics* 66: 355–366
- Stenvik A, Mjör I A 1970 Pulp and dentin reactions to experimental root intrusion. A histologic study of the initial changes. *American Journal of Orthodontics* 57: 370–385
- Van der Linden F P G M, Duterloo H S 1976 Development of the human dentition—an atlas. Harper and Row Publishers, Hagerstown, Maryland
- Zander H A, Hürzeler B 1958 Continuous cementum apposition. *Journal of Dental Research* 37: 1035–1044





Copyright of European Journal of Orthodontics is the property of Oxford University Press / UK and its content may not be copied or emailed to multiple sites or posted to a listserv without the copyright holder's express written permission. However, users may print, download, or email articles for individual use.